

# Automatic Texture analysis of cartilage for early detection of osteoarthritis

Anjani<sup>1</sup>, Sanjeev Kubakaddi<sup>2</sup>

<sup>1</sup>PG Scholar, Department of Electronic and Communication Engineering,  
Reva Institute of technology and management  
Bangalore-64.  
anjani7978@gmail.com

<sup>2</sup> Director ITIE Knowledge Solutions  
Bangalore.  
sanjeev@itie.in

**Abstract:** *Osteoarthritis (OA) is the most commonly occurring chronic disease affecting elder population. OA characterized by the degenerative change in the knee cartilage. Early detection of OA will be very useful for medical treatments. Osteoarthritis symptoms are swelling, loss of movement, severe pain, decrease in the function of the joint. This work is to segment the cartilage automatically from the knee MRI. Texture algorithm applied on the segmented cartilage region. This is checking the biochemical properties of the cartilage. The fluid content in cartilage region increases with Joint Space Width (JSW). Micro texture descriptors (MTD) algorithms are used for the texture analysis.*

**Keywords:** cartilage, MRI, osteoarthritis, MTD.

## 1. Introduction

Medical imaging is the process of creating visual representation of the interior part of a body for clinical analysis and treatments. Many algorithms are used to enhance the images. Manual analysis of the images may leads to human mistakes, so the automatic analysis is commonly used in present days.

Osteoarthritis commonly affects elder population. OA is characterized by the degenerative changes in the cartilage, bone, ligament, menisci. Early detection helps to understand disease condition and treatment option [1]. Cartilage is the ultra-slippery high quality hyaline material that covers the ends of the bone, which is helpful to absorb shocks between femur (thigh bone) and tibia (shin bone). Cartilage covers patella (knee cap) – femoral joint and femoral- tibia joint. But the pressure will be more on femoral-tibia cartilage [2]. Healthy cartilage helps to absorb the shock of movement. In OA, the top layer of the cartilage brakes down and wears away, leads to bone under cartilage rub together [5]. The rubbing causes pain, swelling and loss of motion. After the age 60 years it estimated that 43% of women and 25% of men affected by OA.

OA early detection is crucial to understand the disease status, decision making and clinical treatments. It is traditionally diagnosed with radiographs to demonstrate joint space width (JSW) and osteophytes. To improvement in soft tissue depiction and enhance OA diagnosis magnetic

resonance imaging (MRI), ultrasound (US), optical coherence tomography (OCT).

OA usually happens over time, this is because of:

- Obesity.
- Getting older.
- Repetitive joint injury.
- A genetic defect in joint cartilage.
- More stress on the cartilage.
- Joints that are not properly formed.

OA symptoms are as follows:

- Joint pain and stiffness.
- Swelling at the joint.
- Ligament tear.
- Cracking or grinding noise with joint movement.
- Decreased function of joints.

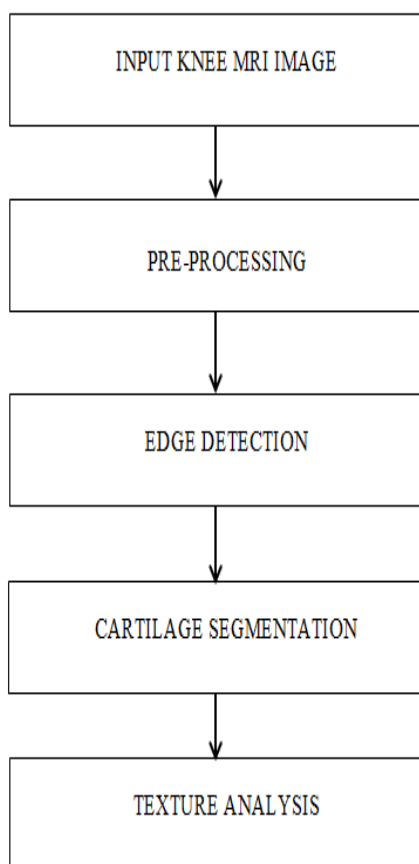
Co-occurrence matrix method is the most commonly used texture segmentation algorithm but this will not work properly on the cartilage segmentation. Since cartilage is the low contrast region it is very difficult to segment automatically. MTD uses neighbours to detect the homogeneity in the image regions.

Methods and test results are explained briefly in the further sections.

## 2. Methods and Materials:

For this study, T2 map sagittal view knee MR images are used. The echo time is 88ms and repetition time is 3800ms. Image set consist of three kinds of images those types are normal knee, doubtful KOA, KOA. The proposed method automatically segment the cartilage region and texture algorithm applied on it.

The proposed method is as follow:



**Figure 1:**Proposed methodology of automatic texture segmentation

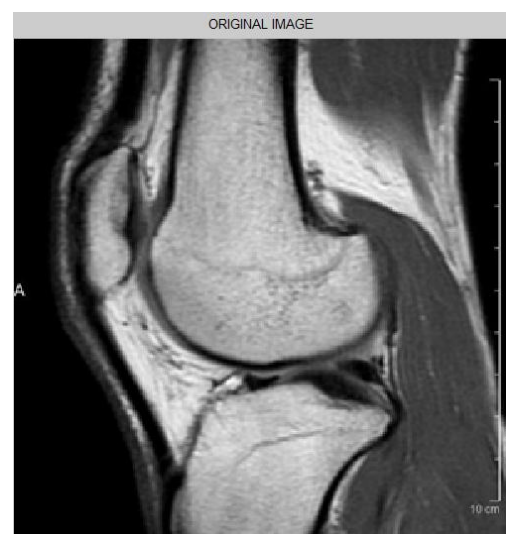The proposed method consists of two methods:

1. Automatic segmentation.
2. Texture analysis.

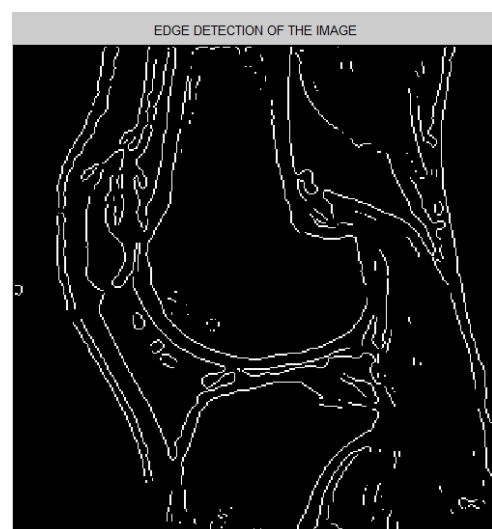
### 2.1 Automatic segmentation:

The input MRI images are preprocessed before segmenting. Since the cartilage is the low contrast region preprocessing steps improve the appearance of the cartilage. Cartilage is the very thin region it is very difficult to segment.


The preprocessing steps include contrast enhancement methods, filtering methods and thresholding. The contrast enhancement method improves the appearance of the cartilage; filters are used to remove the high frequency components present in the knee MRI. Thresholding followed by edge detection helps to avoid some unnecessary edge components.



**Figure 2:** Input image.



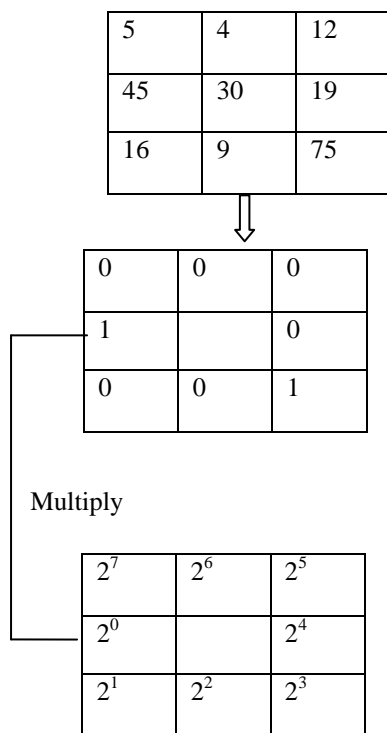
**Figure 3:** Thresholded image.



**Figure 4:** Mask used.

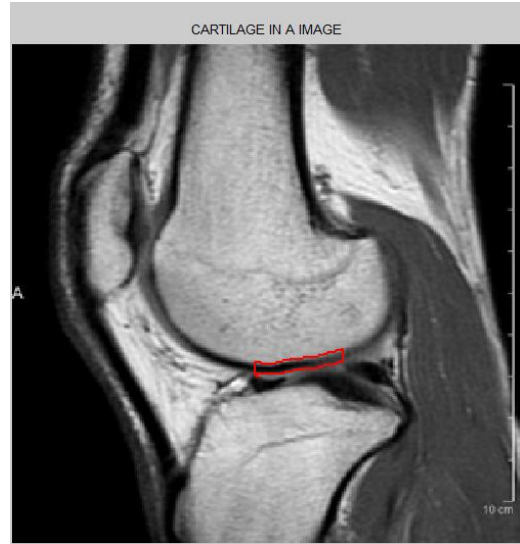
## 2.2 Micro Texture Descriptor:

MTD algorithm uses  $3 \times 3$  local neighborhood matrix with  $p_c$  center pixel and  $p_i$   $i=1,2,\dots,7$  represents the neighbors of  $p_i$ . Using  $3 \times 3$  window MYD value of the center pixel is calculated. If center pixel  $p_c$  is greater than or equal to  $p_i$  then that position is replaced by 1 else that is replaced by zero; like hard thresholding. Later  $p_i$  is multiplied with  $2^i$ , addition of all  $p_i \times 2^i$  is the new MTD value for the center pixel. Same method is repeated for all the pixels in a image.




**MTD= 1+ 8=9.**


**Figure 5 :** MTD algorithm.



**Figure 6:** Cartilage in a image.



**Figure 7:** MTD algorithm applied on the healthy cartilage.



**Figure 8 :** MTD algorithm applied on the OA cartilage.

In figure 7 and in 8 we can clearly see that the yellow color portion is dominating in figure 8 which represents the degeneration of the cartilage region .

### 3. Conclusion:

The method is implemented in MATLAB software which make use of some morphological operations, texture algorithms. Cartilage is situated in the middle of the knee MRI so mask is used to segment the cartilage region. The more yellow color will show the degenerative part in the cartilage. this method gives the automatic segmentation of the cartilage in a knee MRI images

### References

- [1]. Hilly J. Braun, Garry E. Gold, "Diagnosis of osteoarthritis: Imaging", BON-09483; No. of pages: 1-11
- [2]. Harini, S. Kubakaddi, " Measurement of Cartilage Thickness for Early Detection of Knee Osteoarthritis (KOA)" IEEE Trans 2013, page no:208-211
- [3]. M. S. Mallikarjuna Swamy and M.S.Holi, " Knee Joint Cartilage Visualization and Quantification in Normal and Osteoarthritis", Proceedings of 2010 International Conference on Systems in Medicine and Biology 16-18 December 2010, IIT Kharagpur, India
- [4]. S. Kashyap, YinYin, Milan Sonka, "Automated analysis of cartilage morphology", 2013 IEEE 10th International Symposium on Biomedical Imaging, Pg no:1300-1303.
- [5]. U.S. Department of Health and Human Services Public Health Service, "What is osteoarthritis", page no:1-4.
- [6]. G. Chetty, J. Scarvell, S. Mitra, "Fuzzy Texture Descriptors For Early Diagnosis Of Osteoarthritis", IEEE Trans 2013, Pg no:1-6.