

# Implementation of Automatic Retina Exudates Segmentation Algorithm for Early Detection with Low Computational Time

**B. SUMANJALI** (M.tech.)<sup>1</sup> **K. NAGIAH** professor Ph.D<sup>2</sup> **B. ANITHA** Associate professor<sup>3</sup>

Department of electronics and communications engineering

Guru Nanak Institutions-technical campus, Ibrahimpatnam, T.S. 501506-INDIA

## Abstract

In the world, Diabetic Retinopathy is the leading cause of vision loss. Early symptoms of this disease are exudates, so early diagnosis and treatment at right time is very important to prevent blindness. For a particularly long time, automatic diagnosis of diabetic retinopathy from digital fundus images has been an active research topic in the medical image processing community. In this work, two new methods for the detection of exudates are presented which do not use a supervised learning step; therefore, they do not require labelled lesion training sets which are time consuming to create, difficult to obtain and prone to human error. We introduce a new dataset of fundus images from various ethnic groups and levels of DME which we have made publicly available. Experimental results show that proposed yields better results over state of art methods.

**Keywords:** fundus images, diabetic retinopathy (DR), level set, segmentation, mathematical morphology, computer-aided diagnosis, retina normalization

## 1. INTRODUCTION

Diabetic retinopathy (DR) association with diabetes caused poor vision and its early detection helps to reduce its impact to majority level. Exudates are early signs of Diabetic Retinopathy. In color retinal images, they appear as yellow-white structures of different sizes. Retinal images named color fundus images are used to detect exudates in retinal images. The following figure depicts the abnormal retinal image with detailed features and exudates based on unhealthy fundus image. Once detected during retinal examination, it demands immediate treatment ranging from glycemic and blood pressure control, to laser surgery.

Diabetic Retinopathy (DR) is an eye disease which occurs due to diabetes. It damages the small blood vessels in the retina resulting in loss of vision. The risk of the disease increases with age and therefore, middle aged and older diabetics are prone to Diabetic Retinopathy. The National Eye Institute estimates that 40 to 45 percent of Americans

having diabetes are affected by diabetic retinopathy due to which around 24,000 people become blind every year. Symptoms of diabetes retinopathy do not surface until visual damage to the retina has occurred, usually by partial vision. Therefore regular eye screening is necessary to provide early diagnosis and treatment before significant damage is caused to the retina as it potentially reduce the risk of blindness in these patients by 50%. An early detection of DR enables laser therapy to be performed to prevent or delay visual loss and may be used to encourage improvement in diabetic control.

Manual detection of exudates by ophthalmologists is laborious as they have to spend a great deal of time in the analysis and diagnosis of retinal photographs. Automated screening techniques for exudates detection have great significance in saving cost, time and labour. Image processing techniques for exudates detection can help in

extracting the location and size of exudates in the retinal images. In color fundus images they appear as yellow–white deposits (see Fig. 1). Detecting the presence of hard exudates (HE) in different areas of retina is now considered a standard method to assess DME from color fundus images.

In automatic disease detection system can significantly reduce the load of experts by limiting the referrals to those cases that require immediate attention. The reduction in time and effort will be significant where a majority of patients screened for diseases turn out to be normal. In this paper we present two variations of a new exudate segmentation method that falls into the category of thresholding methods which do not require supervised learning. By avoiding a supervised learning step, we prevent common issues with human segmentation inconsistencies.

## 2. WHAT IS DIABETIC RETINOPATHY?

Diabetic retinopathy, the most common diabetic eye disease, occurs when blood vessels in the retina change. Sometimes these vessels swell and leak fluid or even close off completely. In other cases, abnormal new blood vessels grow on the surface of the retina. The retina is a thin layer of light-sensitive tissue that lines the back of the eye. Light rays are focused onto the retina, where they are transmitted to the brain and interpreted as the images you see. The macula is a very small area at the center of the retina. It is the macula that is responsible for your pinpoint vision, allowing you to read, sew or recognize a face. The surrounding part of the retina, called the peripheral retina, is responsible for your side — or peripheral — vision.

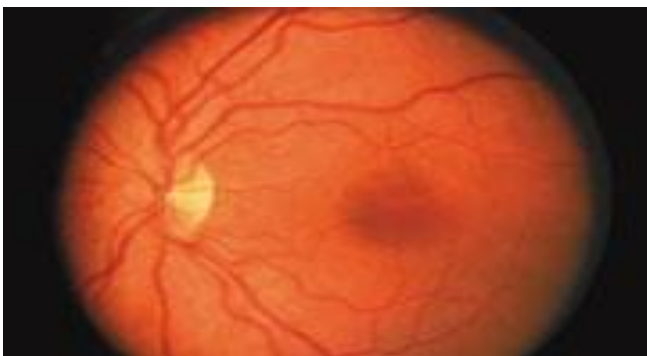

Fig.2.1: A normal retina

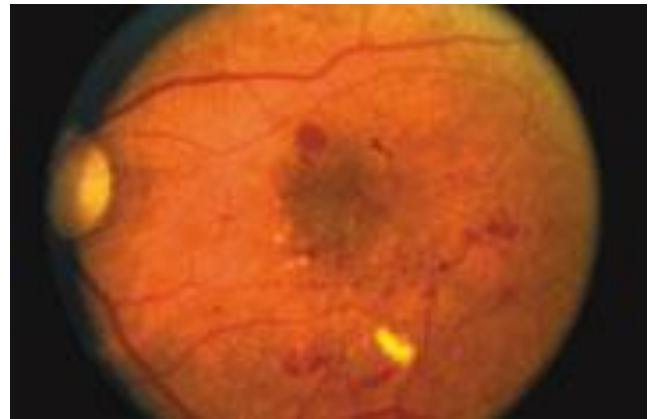


Fig.2.2: A retina showing signs of diabetic retinopathy

Diabetic retinopathy usually affects both eyes. People who have diabetic retinopathy often don't notice changes in their vision in the disease's early stages. But as it progresses, diabetic retinopathy usually causes vision loss that in many cases cannot be reversed.

## 3. EXISTING METHODOLOGIES

Blood vessel segmentation in retinal images is attained by classifying each image pixel as vessel or non-vessel based on the local image features. In general, there are two basic approaches for blood vessel segmentation in retinal images. The algorithms used for the segmentation of blood vessels are broadly classified as pixel processing-based methods and vessel tracking methods

Pixel processing-based methods generally consist of two phases. In the first phase an enhancement procedure is applied which selects an initial set of pixels which are further processed and ensured as vessels in the second phase.

. The retinal vessel segmentation method presented by Mendonça and Campilho consists of three processing phases. The first phase is the pre-processing phase in which background normalization of monochromatic input image is attained initially and then thin vessel enhancement procedures are used. In the second phase, the vessel centre line candidate points are selected first and then these candidate points are joined and then validation of these vessel centre line segment candidates is achieved. In the third phase vessels with different widths are enhanced and

processed using binary morphological reconstruction technique and finally vessel filling is achieved. Soares et al. have proposed an algorithm in which supervised classification technique is applied for the segmentation of retinal vessels. In this technique retinal blood vessels are detected using Gabor wavelets by representing each pixel by a feature vector and then by using Bayesian classifier with Gaussian mixtures, each pixel is classified as a vessel or non-vessel pixel. Chaudhuri et al. have proposed the concept of matched filter detection, where twelve rotated versions of 2-D Gaussian shaped templates are used to explore vessel segments along all possible directions and the resultant image produced is the binary representation of the retinal vasculature.

#### 4. PROPOSED METHODOLOGY

A proposed algorithm was written for automatically detecting optic disk and exudates in the retinal images. The algorithm was developed based on fundus images. The type of DR presented in the images was exudates.

The goal of the paper is detection of the non-proliferative stage of DR which is exudates so that the disease can be managed appropriately to decrease the chances of vision impairment.

The representation of an image in RGB color space allows to studying separately the different channels of the spectral response. The three channels are (red, green and blue) each of which has intensity value ranging between 0 and 255.

Exudates detection faces some of problems that effect on the efficiency of any detecting algorithm. One of the major problems faces exudates detection is the color similarity between optic disc and exudates. Other thing is the recognition of false exudates

##### A. Pre-Processing

The first step in this work is to element the optic disc. Fundus image is an RGB color image, in general RGB images consist of three channels (red, green, and blue), this feature will investigate in this paper localization of the optic disc. This can be accomplished by separation the retina of

image to three channels and using only two of them (red and green channels), the blue channel is characterized by low contrast and does not contain much information. The vessels are visible in the red channel but this channel usually contains too much noise or it is simply saturated, since most of the features emit a signal in the red channel. While the green component of the color retina image gives the best result in the contrast of blood vessels (darker blood vessels on a bright background). Therefore, the green channel of the image is used in the automated analysis of fundus images.

Our approach uses the green channel  $I_g$  of the image and the  $I_i$  channel from the HSI colour space. We start the analysis by estimating the background with a large median filter, whose size is 1/30 the height of the fundus image on  $I_i$ . This approach has been used previously and has great computation performance advantages over other methods.

##### B. Segmentation

The main objective of segmentation is to group the image into regions with same characteristics. The goal of the segmentation is to simplify and /or change the representation of an image into something that is more meaningful and easier to analyze. Image segmentation is typically used to locate objects and boundaries (lines, curves etc.) in the images. The result of image segmentation is a set of segments that collectively cover the entire image, or a set of contours extracted from the image.

##### C. Detection of Optic Disc

The optic disc is the exist point of retinal nerve fibers from the eye and the entrance and exist point for the retinal blood vessels. It appears with similar intensity, colour and contrast to other features on the retinal image. While blood vessels also appear with high contrast as the optic disc, the green channel of the image with morphological closing operator on the intensity channel will help to eliminate the vessels which may remain in the optic disc region. A flat, octagonal structuring element with a fixed radius of fifteen (SE - morphological structuring element) was used

##### D. Artificial Neural Network (ANN)

An Artificial Neural Network is data information processing paradigm that is inspired by biological nervous systems, for instance the brain process data information. The novel structure of the information processing system is an essential element of this paradigm. The network function is determined by the connections between elements, identified as neurons working to solve specific problems. An ANN is defined for a specific application such pattern recognition, system identification or data classification through a learning process.

Classes	Binary Output
Normal	00
Non-CSME	01
CSME	10

Table 3.1 Binary output for three classes

## 5. RESULTS

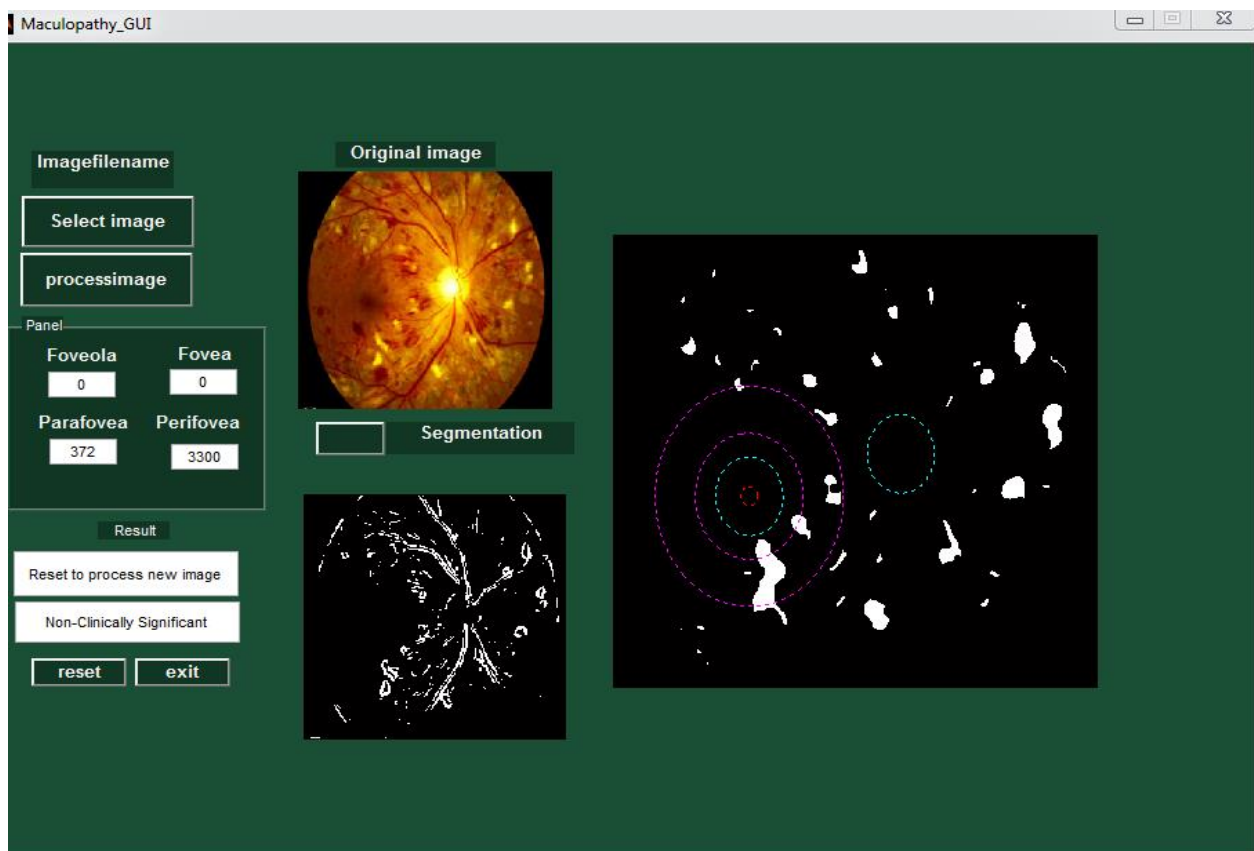


Fig.2.2: Maculopathy GUI- Original image and segmentation

## 6. CONCLUSION

In the literature various methods provide different performances in extraction of blood vessel, Localization of the OD and segmentation of DR lesions. An image database, ground truth and evaluation methodology were proposed for evaluating and comparing methods for automatic detection of diabetic retinopathy. The results are particularly encouraging especially because of the comparison with the

other techniques by Sopharak et al. and Sanchez et al. The method by Sanchez et al. is somewhat close to ours tests, however, the image normalisation procedure gives a substantial computational advantage to our method. This is a simplistic method for DME diagnosis, but does provide a baseline of the possible screening performances that can be achieved employing the output of the segmentation as a classification feature.

## REFERENCES

- [1] R Phillips, J Forrester, and P Sharp, "Automated detection and quantification of retinal exudates," *Graefes Arch Clin Exp Ophthalmol*, vol. 231,no. 2,pp. 90-94,Feb 1993.
- [2] C I Sanchez,M Garcia, A Mayo,M I Lopez,and R Homero, "Retinal image analysis based on mixture models to detect hard exudates.," *Medical Image Analysis*, vol. 13,no. 4,pp. 650- 658,Aug 2009.
- [3] C Sinthanayothin, J F Boyce, T H Williamson, H L Cook, E Mensah, S Lal, and D Usher, "Automated detection of diabetic retinopathy on digital fundus images," *Diabetic Medicine*, vol. 19,no. 2,pp. 105-112,Feb 2002.
- [4] H Li and O Chutatape, "Automated feature extraction in color retinal images by a model based approach," *IEEE Transactions on Biomedical Engineering*, vol. 51, no. 2,pp. 246-254,Feb 2004.
- [5] T Walter,J K Klein,P Massin,and A Erginay, "A contribution of image processing to the diagnosis of diabetic retinopathydetection of exudates in color fundus images of the human retina.," *IEEE Transactions on Medical Imaging*, vol. 21,no. 10,pp. 1236-1243,Oct 2002.
- [6] Akara Sopharak:, Bunyarit Uyyanonvara, Sarah Barman, and Thomas H Williamson, "Automatic detection of diabetic retinopathy exudates from non-dilated retinal images using mathematical morphology methods.," *Computerized Medical Imaging and Graphics*, vol. 32,no. 8,pp. 720-727,Dec 2008